

Morphometric Measurements of the Corpus Callosum in Juvenile Myoclonic Epilepsy Patients and Their Prognostic Value in Disease Course

Ümmühan Eğilmez¹, Selda Keskin Güler²

¹Kırıkkale High Specialization State Hospital, Clinic of Neurology, Kırıkkale, Türkiye

²University of Health Sciences Türkiye, Ankara Training and Research Hospital, Clinic of Neurology, Ankara, Türkiye



Ümmühan Eğilmez MD,

Cite this article as: Eğilmez Ü, Keskin Güler S. Morphometric measurements of the corpus callosum in juvenile myoclonic epilepsy patients and their prognostic value in disease course. *Arch Epilepsy*. 2026;32(2):41-45.



Corresponding Author: Ümmühan Eğilmez, MD, Kırıkkale High Specialization State Hospital, Clinic of Neurology, Kırıkkale, Türkiye, **E-mail:** ummula704@gmail.com

Received: 03.10.2025 **Accepted:** 08.12.2025 **Epub:** 29.01.2026 **Publication Date:** 12.05.2026

DOI: 10.4274/ArchEpilepsy.2025.25214



Copyright© 2026 The Author(s). Published by Galenos Publishing House on behalf of Turkish Epilepsy Society.

This is an open access article under the Creative Commons Attribution-NonCommercial-NoDerivatives 4.0 (CC BY-NC-ND) International License.

Abstract

Objective: Juvenile myoclonic epilepsy (JME) is an idiopathic generalized epilepsy syndrome with age-dependent onset. The corpus callosum (CC), the largest commissural pathway connecting the two cerebral hemispheres, has been reported to undergo structural alterations in epilepsy. However, data regarding morphometric CC changes in JME patients and their prognostic implications remain limited. This study aimed to determine whether regional differences exist in CC morphometric measurements in JME patients and whether these measurements have prognostic value.

Methods: Magnetic resonance imaging scans of 40 JME patients and 20 age- and sex-matched healthy controls were evaluated. CC measurements were obtained from midsagittal T1-weighted images and included the anterior-posterior (A-P) diameter and the perpendicular diameters of the genu, truncus, and splenium.

Results: A total of 40 patients with JME and 20 healthy controls were included. The genu thickness of the CC was significantly reduced in patients compared with controls, whereas the truncus, splenium, and A-P diameters did not differ. In sex-based analyses, male patients showed a greater A-P diameter than female patients, while no sex differences were observed among controls. No correlations were identified between CC measurements and age, disease duration, seizure type, or seizure frequency. Patients receiving polytherapy and patients treated with valproic acid exhibited significantly larger A-P diameters than patients receiving monotherapy and patients treated with levetiracetam, respectively.

Conclusion: JME is associated with region-specific structural alterations of the CC, particularly a reduced thickness of the genu. These changes appear unrelated to clinical severity markers such as seizure type, frequency, or disease duration, suggesting a predominantly developmental or genetic basis. The enlarged A-P diameter observed in male patients and those receiving valproic acid or polytherapy may reflect sex- or treatment-related influences on callosal morphology. Further prospective studies using advanced imaging modalities are needed to clarify the clinical significance of these findings.

Keywords: Juvenile myoclonic epilepsy, corpus callosum, morphometry, prognosis, magnetic resonance imaging

INTRODUCTION

Juvenile myoclonic epilepsy (JME), a common idiopathic generalized epilepsy syndrome, typically emerges during adolescence and is characterized by irregular, arrhythmic myoclonic jerks that often occur shortly after awakening, and is associated with a genetic predisposition and a generally favorable response to antiseizure medications. Generalized tonic-clonic seizures (GTCS) are frequently reported, while absence seizures occur less commonly. Electroencephalography classically demonstrates generalized spike-and-wave or polyspike-wave discharges, and photosensitivity is frequently observed.¹

The corpus callosum (CC), the largest commissural fiber tract, plays a critical role in interhemispheric integration of motor, sensory, and cognitive functions. Its subregions—genu, truncus, isthmus, and splenium—may exhibit structural variability due to variations in myelination, developmental anomalies, and demographic or clinical factors.²⁻⁶

The CC has been implicated in seizure propagation, with callosotomy studies suggesting involvement in both excitatory and inhibitory interhemispheric mechanisms. Although neuroimaging is not required for the diagnosis of JME in neurologically normal patients, increasing evidence indicates structural and functional abnormalities within the thalamocortical and frontal networks. Advanced imaging modalities have reported alterations in cortical gray matter, frontal lobe organization, CC morphology, and broader white matter connectivity.⁷⁻¹¹

While CC abnormalities have been described in several epilepsy syndromes,¹²⁻¹⁴ morphometric changes specific to JME remain insufficiently characterized. This study aimed to evaluate regional CC morphometry in JME and to explore potential associations with clinical characteristics.

METHODS

This study was approved by the University of Health Sciences Türkiye, Ankara Training and Research Hospital Clinical Research Ethics Committee (approval no: 390/2020, date: 20.08.2020). Forty patients with JME aged ≥ 20 years who were followed at a tertiary epilepsy clinic and 20 age- and sex-matched healthy controls were included. Exclusion criteria were age < 20 years (due to incomplete CC development), use of non-antiepileptic drugs, intellectual disability, comorbid conditions, alcohol or substance use, and refusal to participate. Written informed consent was obtained. JME diagnosis was based on the 1989 the International League Against Epilepsy classification and the 2011 Avignon and the 2012 The Hague consensus criteria.^{1,15} Clinical and demographic data (age, sex, age at onset, disease duration, seizure type and frequency, and antiepileptic drugs) were recorded for patients; only demographic data were collected from controls.

Magnetic resonance imaging (MRI) scans with 3D T1-weighted sequences were used to obtain midsagittal images of the CC. Measurements included anterior-posterior (A-P) perpendicular diameters of the genu, truncus, and splenium. The maximum CC length was measured on midsagittal slices, with perpendicular lines used to obtain regional diameters. All measurements were manually performed by the same researcher.

Statistical Analysis

Data were analyzed using SPSS. Categorical variables were expressed as counts and percentages; continuous variables were expressed as mean \pm standard deviation or median (minimum-maximum). Normality was assessed by visual inspection and the Kolmogorov-Smirnov and Shapiro-Wilk tests. Non-normally distributed data were compared using the Mann-Whitney U or Kruskal-Wallis tests; normally distributed data were compared using the independent t-test or analysis of variance. The chi-squared test was applied to categorical variables. Correlations between numerical variables were examined using Spearman's rank correlation test. A p-value 0.05 was considered significant.

MAIN POINTS

- This study investigated the morphometry of the segments of the corpus callosum (CC).
- These measurements were compared between juvenile myoclonic epilepsy (JME) patients and a healthy population.
- The results showed that the CC anterior-posterior diameter was thinner in females than in males.
- JME patients showed thinning of the CC genu, and no relationship was found between the morphological measurements of the CC segments and disease duration, age at onset, seizure type, or seizure frequency.

RESULTS

The study population was divided into two groups: patients (n=40) and controls (n=20). The patient group ranged in age from 21 to 47 years (mean age, 33.1 years) and consisted of 28 females and 12 males. The control group comprised 13 females and 7 males, with ages ranging from 20 to 50 years (mean age, 34.1 years). There were no statistically significant differences between the groups in age or gender distribution ($p > 0.05$). In the patient group (n=40), the disease duration ranged from 3 to 40 years, with a mean of 18.2 years. The age at first seizure in the patient group ranged from 2 to 30 years, with a mean of 14.7 years. In the patient group (n=40), 23 patients (57.5%) exhibited GTCS combined with myoclonus and absence seizures, while 17 patients (42.5%) had GTCS and myoclonus without absence seizures (Table 1).

Regarding antiseizure medications, 20 patients (50%) were using levetiracetam (LEV), 24 (60%) valproic acid (VPA), and 3 (7.5%) lamotrigine (LTG). Median daily doses were 1000 mg for both LEV and VPA, and 150 mg for LTG (Table 1). Patients were classified according to seizure frequency, as detailed in Table 2.

Among those with myoclonic seizures, 55% were seizure-free during follow-up. Seventy-five percent of patients with GTCS were seizure-free. Among those with absence seizures, 60.9% were seizure-free. Full seizure frequency distributions are shown in Table 2.

The MRI measurements of the CC were compared between the patient and control groups, revealing a statistically significant difference in the genu measurements ($p < 0.05$). These findings are presented in Table 3 and illustrated in Figure 1.

Table 1. Demographic and clinical characteristics of the study groups

	Patient group	Control group	p-value
Age (years)	33.1 \pm 7.6	34.1 \pm 8.7	0.648
Gender (female/male) (n)	28/12	13/7	0.922
Seizure type (n) (myoclonus/GTCS/absence)	40/40/23		
Disease duration (years) [mean (min-max)]	18.2 (3-40)		
Age at first seizure (years) [mean (min-max)]	14.7 (2-30)		
Drug, mg (median dose, min-max)			
LEV (n=20)	1000 (500-2000)		
VPA (n=24)	1000 (250-1500)		
LTG (n=3)	150 (25-200)		

GTCS: Generalized tonic-clonic seizures, LEV: Levetiracetam, VPA: Valproic acid, LTG: Lamotrigine

Table 2. Seizure frequency distribution in the patient group

	GTCS (n=40)	Myoclonus (n=40)	Absence (n=23)
Seizure-free	30 (75%)	22 (55%)	14 (60.9%)
≤ 1 seizure/month	7 (17.5%)	7 (17.5%)	7 (30.4%)
≤ 1 seizure/week	3 (7.5%)	5 (12.5%)	1 (4.3%)
> 2 seizures/week	-	6 (15%)	1 (4.3%)

GTCS: Generalized tonic-clonic seizures

In the control group, no sex-related differences were identified in CC measurements. In the patient group, males had a significantly larger A-P diameter than females ($p=0.037$), while measurements of the genu, truncus, and splenium showed no sex-based differences (Table 4 and Figure 2). No significant correlations were observed between age and CC morphometric parameters in either patients or controls ($p>0.05$).

When patients were classified as receiving monotherapy ($n=33$) or polytherapy ($n=7$), the polytherapy group exhibited a significantly larger A-P diameter ($p=0.005$). No significant group differences were found in measurements of the genu, truncus, or splenium (Table 5).

When CC measurements were analyzed by medication type, the thicknesses of the genu, truncus, and splenium did not differ between LEV ($n=13$) and VPA ($n=17$) users. However, patients receiving VPA had a significantly greater A-P diameter ($p=0.041$; Table 6).

In the patient group, potential correlations between disease duration and segmental CC measurements on MRI were investigated; no statistically significant relationships were found ($p>0.05$). Similarly, no significant correlations were found between age at onset and the segmental CC measurements on MRI ($p>0.05$). Potential associations between seizure types (GTCS/myoclonus/absence) and segmental CC measurements on MRI were also investigated, revealing no statistically significant relationships ($p>0.05$).

Table 3. Mean±SD of the MRI measurements and p-values based on the patient and control groups

	Thickness, mm, mean±SD	p-value
Patient's genu	10.6±1.4	0.002
Control's genu	11.9±1.6	
Patient's truncus	5.7±1.8	0.74
Control's truncus	5.8±0.8	
Patient's splenium	9.9±1.5	0.09
Control's splenium	10.6±1.2	
Patient's A-P	66.6±5.1	0.84
Control's A-P	66.5±4.5	

SD: Standard deviation, MRI: Magnetic resonance imaging, A-P: Anterior-posterior

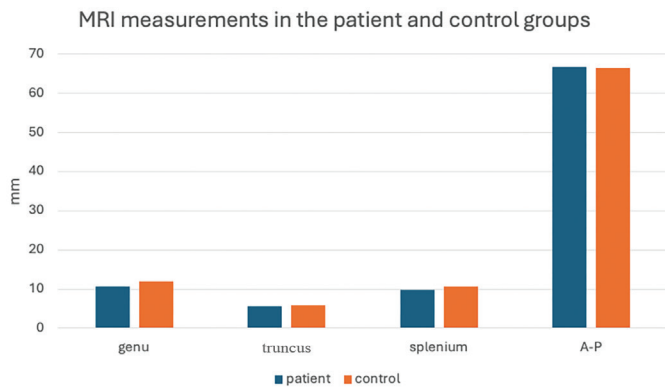


Figure 1. Comparison of MRI measurements between the patient and control groups
MRI: Magnetic resonance imaging, A-P: Anterior-posterior

DISCUSSION

The CC, the largest commissural pathway, demonstrates morphological variability influenced by factors such as myelination, axonal loss, developmental anomalies, genetics, and demographic characteristics, including age and sex.¹⁶⁻¹⁸ Structural CC alterations, particularly in regions responsible for interhemispheric motor network integration, have been previously documented in JME.¹⁹ However, studies specifically assessing sex-related differences in CC morphology within JME cohorts are lacking, as most previous investigations have focused on comparisons between JME patients and healthy controls.^{11,19} Given that sex-related

Table 4. Corpus callosum measurements by sex (patient group)

Patient	Female (n=28)	Male (n=12)	p-value
MRI-genu	22.21	16.50	0.156
MRI-truncus	20.09	21.46	0.734
MRI-splenium	18.91	24.21	0.189
MRI-A-P	17.98	26.38	0.037

MRI: Magnetic resonance imaging, A-P: Anterior-posterior

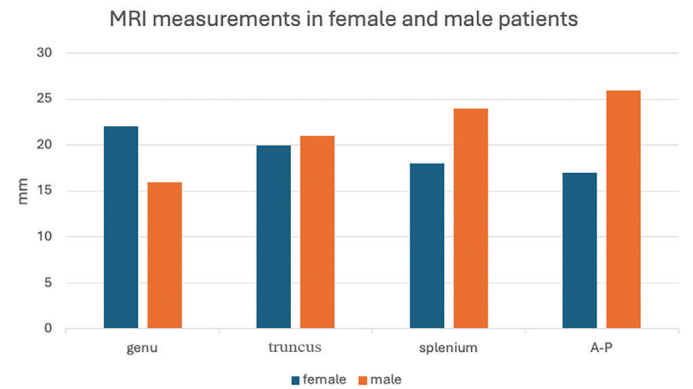


Figure 2. Comparison of MRI measurements between male and female patients in the patient group
MRI: Magnetic resonance imaging, A-P: Anterior-posterior

Table 5. Corpus callosum measurements in monotherapy vs polytherapy

	Polytherapy (n=7)	Monotherapy (n=33)	p-value
MRI-genu	20.86	20.42	0.929
MRI-truncus	14.64	21.74	0.144
MRI-splenium	25.50	19.44	0.213
MRI-A-P	31.64	18.14	0.005

MRI: Magnetic resonance imaging, A-P: Anterior-posterior

Table 6. Corpus callosum measurements in patients using LEV vs VPA

	LEV (n=13)	VPA (n=17)	p-value
MRI-genu	13.96	16.68	0.455
MRI-truncus	15.38	15.59	0.942
MRI-splenium	14.54	16.24	0.598
MRI-A-P	11.81	18.32	0.041

LEV: Levetiracetam, VPA: Valproic acid, MRI: Magnetic resonance imaging, A-P: Anterior-posterior

variations in CC thickness and white matter microstructure are well established in healthy populations,^{20,21} the evaluation of sex-specific CC morphology within JME constitutes an important but underexplored area. In our study, male patients exhibited a significantly greater anteroposterior (A-P) diameter than female patients; no such difference was observed among controls. This suggests that, beyond biological sex, disease-related factors may contribute to callosal variation in JME.

The CC has been implicated in seizure generalization, and corpus callosotomy has been shown to reduce seizure frequency in refractory epilepsy.^{7,22} Conversely, the occurrence of seizures following CC sectioning, or in cases of CC agenesis, suggests a possible inhibitory role for the CC.²²⁻²⁴ Neuroimaging studies have also demonstrated CC abnormalities in epilepsy, including reduced size and altered white matter integrity.²³⁻²⁵ Further evidence indicates that the genu may be a key pathway for seizure propagation.²⁴

Recent findings linking CC atrophy with neuronal dysfunction support this notion. Sandoval Karamian et al.²⁵ reported a reduced size of the genu in newborns with genetic epilepsies, suggesting that white matter abnormalities may be a common feature in genetically mediated epilepsies. The smaller genu measurements observed in our JME cohort are consistent with a potential genetic contribution.

The relationship between CC structure and cognitive function has also been explored. Atkinson et al.²⁶ reported that CC areas were smaller in epilepsy patients and correlated with IQ but not with memory or language dominance. JME, characterized by genetic predisposition and age-specific onset, has been associated with structural abnormalities in thalamocortical and frontal networks.²⁷ Diffusion MRI studies revealed altered microstructural connectivity in the anterior CC and widespread loss of white matter integrity in JME, potentially explaining frontal cognitive dysfunction.^{28,29} Anastasopoulou et al.¹¹ further suggested that callosal abnormalities may distinguish JME from other generalized epilepsies.

While monotherapy remains the standard initial approach to epilepsy management, polytherapy is required for adequate seizure control in more complex cases. Increased antiepileptic drug burden has been reported to influence large-scale neural network organization and white matter microstructure.^{26,27} Therefore, assessing CC morphology across treatment subgroups may illuminate both disease-related structural changes and treatment-response dynamics. To date, no human studies have directly compared CC morphometry between patients treated with VPA and those treated with LEV. However, experimental evidence indicates that VPA exposure can affect myelination and brain volumetry,²¹ and CC morphology has been associated with treatment response in epilepsy.²⁰ The larger A-P diameter observed in VPA-treated and polytherapy patients in our cohort may thus reflect treatment-related effects, longer disease duration, greater seizure burden, or complex interactions among these factors. Evaluating CC morphology in JME with respect to sex and antiseizure medication type addresses a notable gap in the current literature.

Importantly, our study demonstrated a significantly reduced genu thickness in JME patients compared with controls; however, these differences were not associated with disease duration, seizure

type, or seizure frequency. This supports the hypothesis that CC alterations in JME are predominantly neurodevelopmental or genetic rather than secondary to chronic epilepsy.^{29,30} Prior research on this topic has produced mixed findings. Volumetric studies generally report no association between CC size and clinical features,²⁹ consistent with our results. In contrast, diffusion-based studies have identified subtle anterior callosal abnormalities associated with longer disease duration, suggesting that progressive microstructural changes may occur in a subset of patients.^{28,29} These divergent findings likely arise from methodological differences, including variations in imaging modalities (macrostructural vs. microstructural), patient characteristics, and analytic approaches. Overall, the evidence suggests that CC alterations in JME are primarily determined by genetic or developmental factors, although secondary microstructural changes related to disease progression cannot be entirely ruled out.

The absence of correlations between CC morphology and clinical variables in our cohort raises important questions about the temporal evolution of white matter abnormalities in JME, specifically whether they precede seizure onset or emerge over the course of the disease. Future research integrating advanced neuroimaging, larger cohorts, genetic analysis, and neuropsychological assessment is necessary to clarify these mechanisms. Such studies may improve prognostic stratification, inform individualized treatment planning, and support earlier identification of at-risk individuals.

Study Limitations

Participants with comorbid conditions were excluded from the study due to the potential confounding effects on the measurements. Additionally, incorporating genetic and psychological evaluations could further enhance the robustness of our findings.

CONCLUSION

This study demonstrated region-specific alterations in the CC in patients with JME, characterized by reduced genu measurements and increased CC A-P diameter in specific subgroups. These findings suggest that CC involvement in JME may reflect a multifactorial process influenced by biological factors, such as sex, as well as treatment-related characteristics, including antiepileptic drug exposure and polytherapy. The absence of associations between CC morphology and clinical variables, including disease duration and seizure features, supports the possibility that callosal alterations may be related to underlying neurodevelopmental or genetic mechanisms rather than acquired effects of epilepsy. Given the retrospective design and limited subgroup sample sizes, these results should be interpreted cautiously. Prospective studies incorporating advanced imaging methods, larger cohorts, and genetic and cognitive assessments are warranted to clarify the clinical significance of CC changes and determine whether CC morphology may serve as a structural marker in JME.

Ethics

Ethics Committee Approval: This study was approved by the University of Health Sciences Türkiye, Ankara Training and Research Hospital Clinical Research Ethics Committee (approval no: 390/2020, date: 20.08.2020).

Informed Consent: Written informed consent was obtained.

Footnotes

Authorship Contributions

Surgical and Medical Practices: Ü.E., Concept: Ü.E., S.K.G., Design: Ü.E., S.K.G., Data Collection or Processing: Ü.E., Analysis or Interpretation: Ü.E., Literature Search: Ü.E., Writing: Ü.E., S.K.G.

Conflict of Interest: No conflict of interest was declared by the authors.

Financial Disclosure: The authors declared that this study received no financial support.

REFERENCES

- Proposal for revised classification of epilepsies and epileptic syndromes. Commission on Classification and Terminology of the International League Against Epilepsy. *Epilepsia*. 1989;30(4):389-399. [\[Crossref\]](#)
- van der Knaap LJ, van der Ham IJ. How does the corpus callosum mediate interhemispheric transfer? A review. *Behav Brain Res*. 2011;223(1):211-221. [\[Crossref\]](#)
- Hampel H, Teipel SJ, Alexander GE, et al. Corpus callosum atrophy is a possible indicator of region- and cell type-specific neuronal degeneration in Alzheimer disease: a magnetic resonance imaging analysis. *Arch Neurol*. 1998;55(2):193-198. [\[Crossref\]](#)
- Hommer D, Momenan R, Rawlings R, et al. Decreased corpus callosum size among alcoholic women. *Arch Neurol*. 1996;53(4):359-363. [\[Crossref\]](#)
- Meguro K, Constans JM, Courtheoux P, Theron J, Viader F, Yamadori A. Atrophy of the corpus callosum correlates with white matter lesions in patients with cerebral ischaemia. *Neuroradiology*. 2000;42(6):413-419. [\[Crossref\]](#)
- Woodruff PW, McManus IC, David AS. Meta-analysis of corpus callosum size in schizophrenia. *J Neurol Neurosurg Psychiatry*. 1995;58(4):457-461. [\[Crossref\]](#)
- Tanriverdi T, Olivier A, Poulin N, Andermann F, Dubeau F. Long-term seizure outcome after corpus callosotomy: a retrospective analysis of 95 patients. *J Neurosurg*. 2009;110(2):332-342. [\[Crossref\]](#)
- Ghani Zghair MA. Corpus callosum disorders and associated malformations in paediatric epilepsy: MRI analytic study. *J Pak Med Assoc*. 2021;71(Suppl 8)(12):S190. [\[Crossref\]](#)
- Genton P, Gelisse P, Thomas P, Dravet C. Do carbamazepine and phenytoin aggravate juvenile myoclonic epilepsy? *Neurology*. 2000;55(8):1106-1109. [\[Crossref\]](#)
- Woermann FG, Free SL, Koepp MJ, Sisodiya SM, Duncan JS. Abnormal cerebral structure in juvenile myoclonic epilepsy demonstrated with voxel-based analysis of MRI. *Brain*. 1999;122 (Pt 11):2101-2108. [\[Crossref\]](#)
- Anastasopoulou S, Kurth F, Luders E, Savic I. Generalized epilepsy syndromes and callosal thickness: Differential effects between patients with juvenile myoclonic epilepsy and those with generalized tonic-clonic seizures alone. *Epilepsy Res*. 2017;129:74-78. [\[Crossref\]](#)
- Pulsipher DT, Seidenberg M, Morton JJ, Geary E, Parrish J, Hermann B. MRI volume loss of subcortical structures in unilateral temporal lobe epilepsy. *Epilepsy Behav*. 2007;11(3):442-449. [\[Crossref\]](#)
- O'Dwyer R, Wehner T, LaPresto E, et al. Differences in corpus callosum volume and diffusivity between temporal and frontal lobe epilepsy. *Epilepsy Behav*. 2010;19(3):376-382. [\[Crossref\]](#)
- Firat A, Tascioglu AB, Demiryurek MD, et al. Evaluation of corpus callosum morphometry in patients with mesial temporal lobe epilepsy with hippocampal sclerosis. *Surg Radiol Anat*. 2014;36(1):47-54. [\[Crossref\]](#)
- Kasteleijn-Nolst Trenité DG, Schmitz B, Janz D, et al. Consensus on diagnosis and management of JME: from founder's observations to current trends. *Epilepsy Behav*. 2013;28 Suppl 1:S87-90. [\[Crossref\]](#)
- Erdoğan N, Ulger H, Tuna I, Okur A. A novel index to estimate the corpus callosum morphometry in adults: callosal/supratentorial-supracallosal area ratio. *Diagn Interv Radiol*. 2005;11(4):179-181. [\[Crossref\]](#)
- Bleier R, Houston L, Byne W. Can the corpus callosum predict gender, age, handedness, or cognitive differences? *Trends Neurosci*. 1986;9(9):391-394. [\[Crossref\]](#)
- Holloway RL, de Lacoste MC. Sexual dimorphism in the human corpus callosum: an extension and replication study. *Hum Neurobiol*. 1986;5(2):87-91. [\[Crossref\]](#)
- Tae WS, Hong SB, Joo EY, et al. Structural brain abnormalities in juvenile myoclonic epilepsy patients: volumetry and voxel-based morphometry. *Korean J Radiol*. 2006;7(3):162-172. [\[Crossref\]](#)
- Schmied A, Soda T, Gerig G, et al.; IBIS Network. Sex differences associated with corpus callosum development in human infants: a longitudinal multimodal imaging study. *Neuroimage*. 2020;215:116821. [\[Crossref\]](#)
- Menzler K, Belke M, Wehrmann E, et al. Men and women are different: diffusion tensor imaging reveals sexual dimorphism in the microstructure of the thalamus, corpus callosum and cingulum. *Neuroimage*. 2011;54(4):2557-2562. [\[Crossref\]](#)
- Kopeloff N, Kennard MA, Pacella BA, Kopeloff LM, Chusid JG. Section of corpus callosum in experimental epilepsy in the monkey. *Arch Neurol Psychiatry*. 1950;63(5):719-727. [\[Crossref\]](#)
- Andrade CS, Leite CC, Otaduy MC, et al. Diffusion abnormalities of the corpus callosum in patients with malformations of cortical development and epilepsy. *Epilepsy Res*. 2014;108(9):1533-1542. [\[Crossref\]](#)
- Wiesmann UC, Milinis K, Paniker J, et al. The role of the corpus callosum in seizure spread: MRI lesion mapping in oligodendrogliomas. *Epilepsy Res*. 2015;109:126-133. [\[Crossref\]](#)
- Sandoval Karamian AG, Wusthoff CJ, Boothroyd D, Yeom KW, Knowles JK. Neonatal genetic epilepsies display convergent white matter microstructural abnormalities. *Epilepsia*. 2020;61(12):e192-e197. [\[Crossref\]](#)
- Atkinson DS Jr, Abou-Khalil B, Charles PD, Welch L. Midsagittal corpus callosum area, intelligence, and language dominance in epilepsy. *J Neuroimaging*. 1996;6(4):235-239. [\[Crossref\]](#)
- Jiang S, Luo C, Liu Z, et al. Altered local spontaneous brain activity in juvenile myoclonic epilepsy: a preliminary resting-state fMRI study. *Neural Plast*. 2016;2016:3547203. [\[Crossref\]](#)
- Gong J, Chen G, Zhang Z, et al. Microstructural alterations of white matter in juvenile myoclonic epilepsy. *Epilepsy Res*. 2017;135:1-8. [\[Crossref\]](#)
- Kim JH, Suh SI, Park SY, et al. Microstructural white matter abnormality and frontal cognitive dysfunctions in juvenile myoclonic epilepsy. *Epilepsia*. 2012;53(8):1371-1378. [\[Crossref\]](#)
- Gelisse P, Genton P, Raybaud C, Thomas P, Dravet C. Structural brain lesions do not influence the prognosis of juvenile myoclonic epilepsy. *Acta Neurol Scand*. 2000;102(3):188-191. [\[Crossref\]](#)